

## Case report

# Successful transcatheter aortic valve implantation in a high-risk nonagenarian in Sri Lanka


Athauda-arachchi PM<sup>1,2</sup>  <sup>1</sup>General Sir John Kotelawala Defence University, Sri Lanka,<sup>2</sup>Durdans Hospital, Colombo, Sri Lanka

## Article Information

### Corresponding Author

PM Athauda-arachchi

Email: athaudaarachchipm@kdu.ac.lk

 <https://orcid.org/0000-0001-5401-5548> <https://doi.org/10.4038/sljms1.v1i1.6>

Received 03 June 2024

Revised version 15 June 2024

Accepted 02 July 2024

**Conflicts of Interest:** None

## Abstract

Severe calcific aortic stenosis with repeated heart failure hospital admissions carries a high mortality and morbidity in the elderly. Despite a calculated high risk of periprocedural complications, Sri Lanka's first transcatheter heart valve replacement in an over 90-year-old patient in such a clinical condition could be performed with no major in-hospital adverse cardiac or cerebral events. Improved quality of life with freedom from repeated hospitalizations is an important clinical achievement in this age group following transcatheter heart valve therapy.

**Keywords:** degenerative aortic stenosis, high risk transcatheter heart valve interventions, TAVI in nonagenarians

## Introduction

Transcatheter Aortic Valve Implantation (TAVI) is a minimally invasive procedure used to replace a diseased aortic valve. It is particularly relevant for older patients who may be at higher risk for complications from traditional open-heart surgery. Transcatheter heart valve procedures have extended the options for populations hitherto considered high or intermediate risk of surgical heart valve replacements, often demonstrating lower major adverse cardiac and cerebral events.

Whilst many landmark trials of transcatheter heart valve devices excluded the over 90-year-old patients, minimally invasive TAVI performed under local anaesthesia, often less invasive than open-heart surgery, is the only option available for such elderly patients who may not be able to tolerate the surgical aortic valve replacement due to frailty or other comorbidities. It was an unmet need to reduce the risk of end-stage heart failure.<sup>1</sup>

**Cite this article as:** Athauda-arachchi PM. Successful transcatheter aortic valve implantation in a high-risk nonagenarian in Sri Lanka. SLJMS 2024; 1(1): 40-42.



This is an open-access article distributed under the terms of the Creative Commons Attribution 4.0 International License, which permits unrestricted use, distribution and reproduction in any medium provided the original author and source are credited.

In Sri Lanka, the minimally invasive TAVI procedures commenced in 2018, with many successful cases performed in the interim. However, procedures in over the 90-year-old age group have not been considered feasible. We describe the first of such cases performed on a 91-year-old patient, discussing the multiple challenges that must be overcome for a successful outcome.

### Case presentation

A 91-year-old man with recurrent pulmonary oedema and hospital admissions with delayed discharge was being followed up with critical aortic stenosis (Peak gradient 82 mmHg, Mean gradient 42 mmHg, AVA 0.5 cm<sup>2</sup>). ECG showed pre-existing LBBB, Parkinson’s disease, diabetes mellitus, baseline serum creatinine of 2.1 mg/dl, borderline low Hb 10.2 g/dl. A coronary angiogram with minimal contrast demonstrated moderate calcific disease of the left anterior descending and right coronary arteries.

The mortality estimated for a surgical aortic valve replacement was estimated. The EuroSCORE II was 21.57% and STS-Score was 25.6%, indicating a prohibitive risk. The ACC-STS risk of the TAVI procedure was 9.3%, and the patient consented to the procedure.

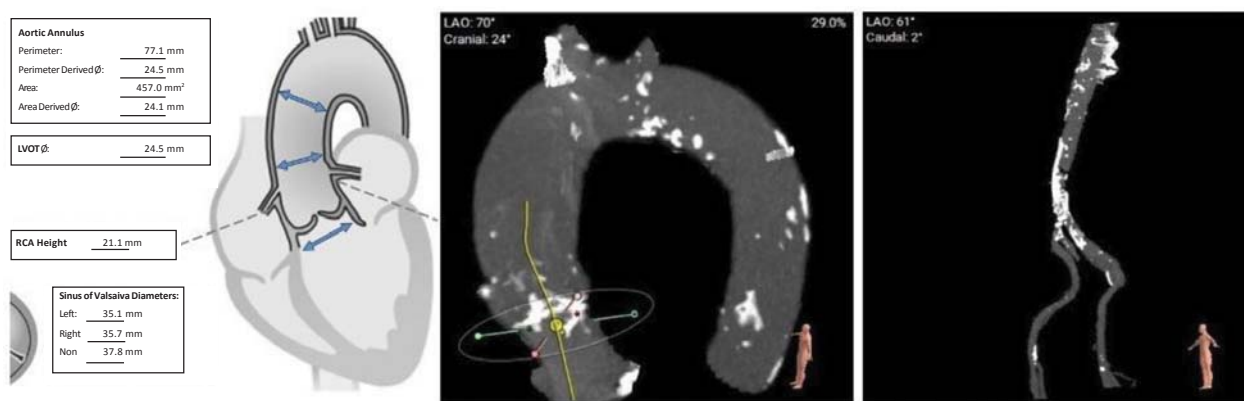
A minimal contrast CT was performed, 3-Mensio software analysis was to assess the aortic valve dimensions and

vessel characteristics and calcifications. Key findings are illustrated in Figure 1.

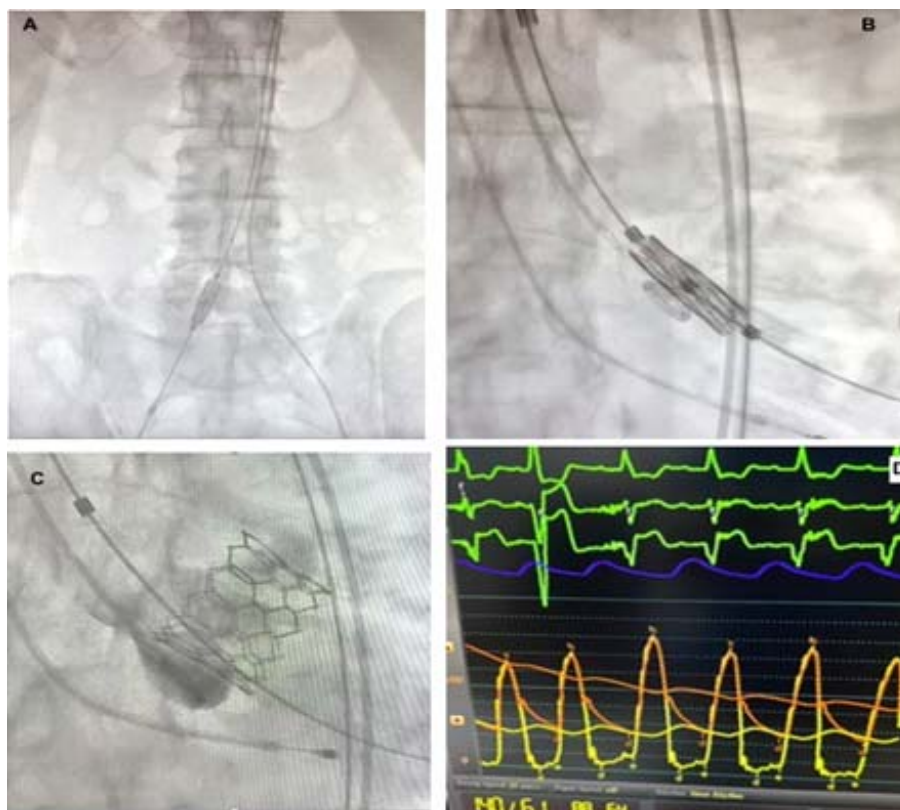
The procedure was undertaken following hydration and renal preparation. Femoral access was undertaken with ultrasound guidance, and local anaesthesia only. Percutaneous pre-closure with Proglide devices, followed by a 14-french Python expandable sheath and a 23.5 mm MyVal TAVI device was advanced through the tortuous calcific aortic anatomy with good flexion control. The device was deployed under rapid pacing. Excellent hemodynamic parameters were noted with no paravalvular leak as shown in Figure 2.

Routine percutaneous closure of femoral access was achieved with good haemostasis. The procedure was completed with 40 ml of diluted contrast, with no evidence of nephropathy.

Despite the calculated high risk, the actual patient outcome was excellent with no perioperative cardiac or cerebral events, and improved serum creatinine to 1.7 mg/dl over the next few days. Patient could be mobilized on day three and discharged. However, as a late event, at one week, patient had a pre-syncopal event and a decision for implantation of a backup single lead pacemaker, illustrating the vulnerabilities of a pre-existing conduction weakness, despite the TAVI valve not showing any in-hospital strain. The patient has since been in excellent clinical status without further hospitalizations.



**Figure 1.** Pre-planning CT, with 3-Mensio analysis. Adequate coronary heights and sinuses were noted despite calcifications in the aortic arch and iliac bifurcation.



**Figure 2.** Advancement of 23.5 mm MyVal device through the 14F Python sheath placed in the right femoral artery [A]. Crimped valve advanced across aortic valve using flexion control [B]. Minimal contrast used for check aortogram post valve deployment [C]. Haemo-dynamic assessment post-deployment shows no significant gradient across the valve and good diastolic pressures [D].

## Discussion and conclusions

TAVI in over 90-year-olds carries a mortality risk 2-fold higher in nonagenarians,<sup>2</sup> compared with patients younger than 90 years of age. However, it may be successfully undertaken despite prohibitive surgical risks. Careful periprocedural planning is needed to avoid major adverse cardiac or cerebral events and nephropathy.

Whilst carrying a risk of cardiac mortality, on a background of overall limited non-cardiac life expectancy, it is still worth noting the key benefits from a successful TAVI procedure to expect in this age group including reduced recovery time, improved quality of life<sup>3</sup> and less hospitalization, as illustrated by this case.

## References

1. Athauda-arachchi P. Advanced interventional cardiac procedures and perioperative care required to prevent the epidemic of end-stage heart disease in Sri Lanka. *Sri Lanka Journal of Medicine* 2019; **28**(1): 54-60. <https://doi.org/10.4038/sljm.v28i1.121>
2. Vlastra W, Chandrasekhar J, Vendrik J, Gutierrez-Ibanes E, Tchétché D, de Brito FS Jr, Barbanti M, Kornowski R, Latib A, D'Onofrio A, Ribichini F, Baan J, Tijssen JGP, Pan M, Dumonteil N, Mangione JA, Sartori S, D'Errigo P, Tarantini G, Lunardi M, Orvin K, Pagnesi M, Sanchez Gila J, Modine T, Dangas G, Mehran R, Piek JJ, Delewi R. Transfemoral TAVR in Nonagenarians: From the Center Collaboration. *JACC Cardiovasc Interv.* 2019; **12**(10): 911-20. doi: 10.1016/j.jcin.2019.02.031
3. Bernard J, St-Louis R, Robichaud M, Kalavrouziotis D, Dumont É, Paradis JM, Babaki S, Rodés-Cabau J, Mohammadi S. Is Transcatheter Aortic Valve Replacement Futile in Patients Over Ninety Years of Age? *CJC Open.* 2023; **5**(10): 784-91.

## Case report


**Severe myelosuppression causing pancytopenia in a patient with Crohn's disease: an uncommon complication of azathioprine**Nimesha SNH<sup>1</sup>, Jayasena H<sup>2</sup> <sup>1</sup>University Medical Unit, Colombo North Teaching Hospital, Ragama, Sri Lanka<sup>2</sup>Faculty of Medicine, General Sir John Kotelawala Defence University, Sri Lanka

## Article Information

## Corresponding Author

H Jayasena

Email: hiru65@hotmail.com

 <https://orcid.org/0000-0001-5175-0803> <https://doi.org/10.4038/sljms1.v1i1.7>

Received 03 June 2024

Revised version 13 June 2024

Accepted 24 July 2024

Conflicts of Interest: None

**Abstract**

Azathioprine, is widely used to treat many diseases as a steroid sparing drug, including inflammatory bowel disease. Whilst it can commonly result in leucopenia, in rare instances, it can cause severe myelosuppression and pancytopenia. We present a patient with Crohn's disease, who developed severe myelosuppression resulting in pancytopenia and neutropenic sepsis secondary to azathioprine use.

**Keywords:** azathioprine, Crohn's disease, diarrhoea, pancytopenia**Introduction**

Azathioprine, a purine analogue, is widely used to treat many diseases as a steroid sparing drug, including inflammatory bowel disease (IBD). It is well absorbed by the gastrointestinal tract and has a serum half-life of 0.2-0.5 hours with biological half-life of 24 hours.<sup>1</sup> Azathioprine exerts its action by inhibiting purine and protein synthesis in lymphocytes.<sup>2</sup> Azathioprine is a prodrug that is converted to 6-mercaptopurine via non-enzymatic nucleophilic attack by sulphhydryl contain products like glutathione in red cells and other tissues. In addition, it also inhibits the proliferation of T lymphocytes, B lymphocytes as well as plasma cells and causes apoptosis of T cells.<sup>2</sup> Whilst it can commonly result in leucopenia, in rare instances, it can cause severe myelosuppression and pancytopenia.

Usually, the dosing of azathioprine is either based on gradual adjustment of the dose or on TPMT gene studies. TPMT activity influences the incidence of adverse effects particularly bone marrow toxicity.<sup>3</sup> The most widely used method is that of by gradual adjustment of dose as genetic studies are widely unavailable and can be costly. Consequently, patients are started on a small dose of azathioprine and the dose is gradually raised to the therapeutic desired range, whilst clinicians monitor for potential complications. There are "dose

**Cite this article as:** Jayasena H, et al. Severe myelosuppression causing pancytopenia in a patient with Crohn's disease: an uncommon complication of azathioprine. SLJMS 2024; 1(1): 43-45.



This is an open-access article distributed under the terms of the Creative Commons Attribution 4.0 International License, which permits unrestricted use, distribution and reproduction in any medium provided the original author and source are credited.

independent” and “dose dependant” side effects of azathioprine. Most common dose independent side effects include gastrointestinal side effects such as anorexia, nausea, vomiting and pancreatitis.<sup>4</sup> The dose dependant side effects on the other hand include infections, bone marrow suppression hepatotoxicity and alopecia.<sup>5</sup> Dose related bone marrow suppression results in neutropenia in approximately 17%, whilst thrombocytopenia occurs in up to 5%.<sup>1,4</sup> Nevertheless severe pancytopenia with azathioprine affecting all three cell lines is not common, with a reported incidence of 0.4-2% of cases in IBD treated with azathioprine.<sup>6</sup>

## Case report

A 15-year-old Sinhalese boy, who had previously been diagnosed three months prior with Crohn’s disease, presented to tertiary centre in Western province, with persistent fever for seven days. Following his initial diagnosis of Crohn’s disease, he was commenced on reducing course of prednisolone as well as azathioprine 25 mg daily, which was later increased gradually to 75 mg over a two-month period. The patient was symptomatically improved with weight gain and appetite noted. Despite improvement in bowel symptoms, he noted that there was increased loss of hair. Two weeks after commencement of increased dose of azathioprine 75mg per day, he presented with severe sore throat, myalgia and fever lasting for one day. There had been no concurrent medications (ayurvedic or herbal) used by the patient.

On examination he was febrile, flushed and the oropharynx appeared inflamed with no pustular formation. The full blood count (FBC) on admission showed severe pancytopenia with white blood cells (WBC) of  $1.3 \times 10^3$ , absolute neutrophil count of  $0.16 \times 10^3$ , Haemoglobin (Hb) of 10g/dl with a platelet count of  $5 \times 10^3$ . Given the high prevalence of Dengue fever in Sri Lanka, the initial suspicion was that of Dengue fever. However, NS 1 antigen done on the day two of fever was negative, along with a negative dengue IgM and IgG. The blood picture demonstrated evidence of pancytopenia with normochromic normocytic anaemia, leukopenia and markedly reduced platelets with evidence of possible bacterial infection. There were no atypical cells noted. The C- reactive protein (CRP) level was 233 with an Erythrocyte sedimentation rate (ESR) of 40 mm on admission. Cultures including blood, urine and throat swab were repeatedly negative. The reticulocyte count was 0.13% with a reticulocyte index of 0.05 showing evidence of bone marrow hypo-proliferation. Hence, he was managed as neutropenic sepsis and azathioprine was withheld on suspicion of possible toxicity.

In treating neutropenic sepsis, the patient was commenced on intravenous piperacillin-tazobactam, after taking

cultures. Along with it, he was commenced on twice daily doses of granular colony stimulating factor (GCSF), following a bone marrow biopsy to identify the cause of severe pancytopenia. The patient responded well to treatment and was afebrile by day three of treatment.

The WBC counts improved with GCSF and by day four, the WBC raised to  $4.30 \times 10^6$ /mL with absolute neutrophil count of  $1.14 \times 10^6$ /mL. However, his platelet count remained slow to respond with a count of only  $4 \times 10^6$ /mL. The other investigations including liver function test, lactate dehydrogenase level and serum creatinine remained normal. The bone marrow demonstrated presence of severe bone marrow suppression with possibility of drug induced bone marrow suppression. Parvo virus antibodies were found to be negative. The chest x ray was completely normal as well as sputum cultures which were negative for acid fast bacilli. Furthermore, GeneXpert studies for tuberculosis and bone marrow tuberculosis polymerase chain reaction test both yielded negative results.

With stopping of the drug and timely treatment of the concomitant neutropenic sepsis, the patient gradually improved. By day ten, patient was asymptomatic with WBC of  $10.84 \times 10^6$ /mL, an absolute neutrophil count of  $6.33 \times 10^6$ /mL, and platelets were  $30 \times 10^6$ /mL. Azathioprine was completely withheld, and patient was switched to biological therapy of infliximab for Crohn’s disease. Prior to commencing on infliximab, screening for HIV, viral hepatitis including cytomegalovirus (CMV) and Epstein Barr virus (EBV) was completed. He remained asymptomatic during the follow up and FBC parameters were persistently within normal range.

## Discussion

Azathioprine is one of the most used drugs to maintain remission in IBD. As the main action of azathioprine is on the lymphocytes, the most common feature of bone marrow suppression is to present as leucopenia. However, in rare instances it can cause severe life-threatening pancytopenia, as it did in our patient. Studies have shown that 1 in 4 patients, who were treated with azathioprine, have developed drug related complications.<sup>7</sup> It is common mostly during the first month of starting azathioprine.<sup>7</sup> Approximately in 20% of the cases, the side effects were severe enough to warrant cessation of treatment.<sup>7</sup> Owing to its side effects, the use of TPMT levels in optimizing and guiding azathioprine treatment in IBD is practised in developed countries.<sup>8</sup> Myelosuppression has been associated with low Thiopurine methyltransferase (TPMT) levels.<sup>9</sup> Unfortunately, due to the high cost of TPMT gene analysis and unavailability, TPMT levels were not sent in this patient prior to starting azathioprine, which could have helped to predict response to treatment. The

above-mentioned patient presented with fever and features of sepsis. It is worth noting that it is common for pancytopenia to present as an underlying infection and neutropenic sepsis. The raised ESR and CRP both suggested the presence of an infection. However, all the peripheral cultures including blood, urine, throat swabs and bone marrow negative for any bacterial or tuberculosis infections. Parvo virus B19 antibodies negative and was done to exclude possible common cause for pancytopenia in young. Furthermore, prior to biological therapy commencement, the patient had screening for HIV, viral hepatitis including cytomegalovirus (CMV) and Epstein Barr virus (EBV) all of which can cause pancytopenia, which were all negative. Bone marrow trephine biopsy showed evidence of severe pancytopenia, without evidence of malignancy and with the possibility of drug induction as suggested by the history. The severe alopecia was also accounted for by azathioprine toxicity, in this patient, given the severe hair loss and pancytopenia, azathioprine was omitted altogether. Following the cessation of azathioprine, both clinical and biochemical parameters returned to normal. Given the short course of illness, with diagnosis only occurring 3 months prior with good nutritional status, it was unlikely that the patient had significant nutritional deficiencies related to Crohn's disease to cause pancytopenia. Inability to check iron studies, vitamin B<sub>12</sub> and folate levels was a limitation in this study.

## Conclusion

Even though the common side effects of azathioprine are not dangerous, there remains few life-threatening side effects such as severe liver injury and severe pancytopenia. Hence vigilant monitoring is required when commencing or on dose adjustment of azathioprine is done. TPMT levels would help to identify those at risk of developing severe side effects due to azathioprine. If proper follow up, necessary investigations and timely interventions are not done, these patients can easily be missed.

## Author Contribution

All authors equally contributed to the study.

## References

1. Huskisson EC. Azathioprine. *Clinics in rheumatic diseases*. 1984; **10**(2): 325-32.
2. Rios-Usuga C, Martinez-Gutierrez M, Ruiz-Saenz J. Antiviral Potential of Azathioprine and Its Derivative 6-Mercaptopurine: A Narrative Literature Review. *Pharmaceuticals* (Basel). 2024; **17**(2): 174.
3. Dong XW, Zheng Q, Zhu MM, et al. Thiopurine S-methyltransferase polymorphisms and thiopurine toxicity in treatment of inflammatory bowel disease. *World J Gastroenterol* 2010; **16**: 3187-95.
4. Weinsilboum RM, Sladek SL. Mercaptopurine pharmacogenetics: monogenic inheritance of erythrocyte thiopurine methyltransferase activity. *American Journal of Human Genetics* 1980; **32**(5): 651.
5. Broekman MMTJ, Coenen MJH, van Marrewijk CJ, et al. More Dose-dependent Side Effects with Mercaptopurine over Azathioprine in IBD Treatment Due to Relatively Higher Dosing. *Inflamm Bowel Dis*. 2017; **23**(10): 1873-81.
6. Telm A, Schaeffeler E, Herlinger KR, et al. Thiopurine treatment in inflammatory bowel disease. *Clin Pharmacokinet* 2007; **46**: 187-208.
7. Chaparro M, Ordás I, Cabré E, et al. Safety of thiopurine therapy in inflammatory bowel disease: long-term follow-up study of 3931 patients. *Inflammatory bowel diseases*. 2013; **19**(7): 1404-10.
8. Warner B, Johnston E, Arenas-Hernandez M, et al. *Frontline Gastroenterology* 2018; **9**: 10-15.
9. Hindorf U, Lindqvist M, Hildebrand H, et al. Adverse events leading to modification of therapy in a large cohort of patients with inflammatory bowel disease. *Aliment Pharmacol Ther*. 2006; **24**: 331-42.